OPTIC NEUROPATHIES

1. **Clinical features**
2. **Special investigations**
3. **Optic neuritis**
   - **Retrobulbar neuritis**
   - **Papillitis**
   - **Neuroretinitis**
4. **Anterior ischaemic optic neuropathy (AION)**
5. **Leber hereditary optic neuropathy**

Signs of optic nerve dysfunction

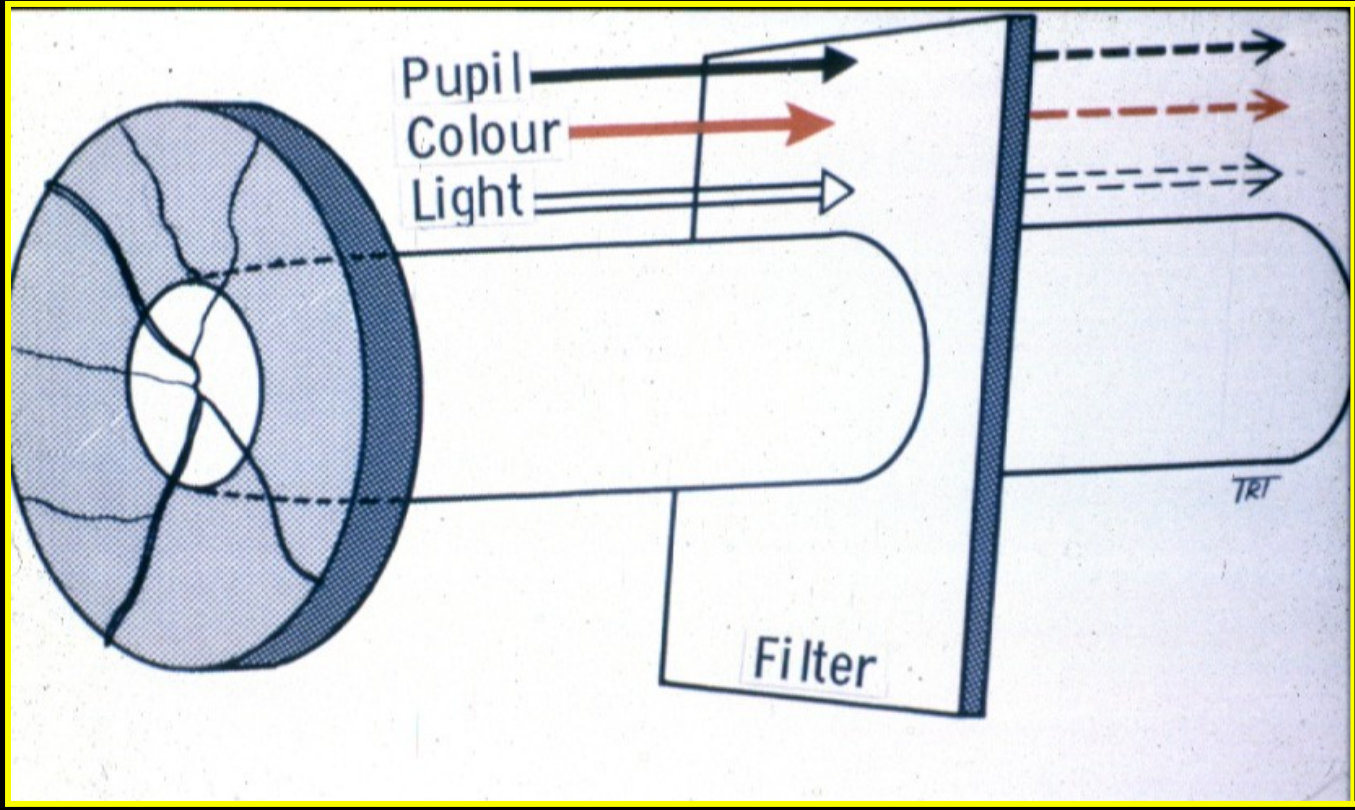

- Reduced visual acuity
- Afferent pupillary conduction defect
- Dyschromatopsia
- Diminished light brightness sensitivity

Applied anatomy of afferent conduction defect

Anatomical pathway	Signs
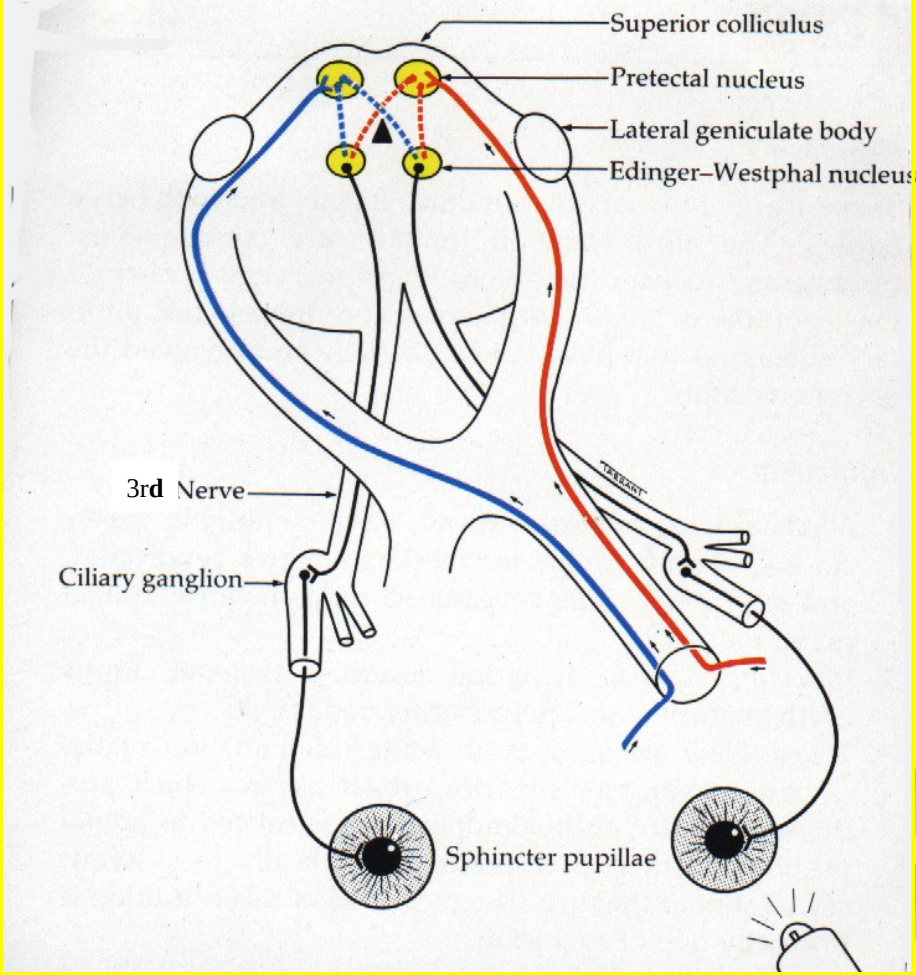	• Equal pupil size • Light reaction - ipsilateral direct is absent or diminished - consensual is normal • Near reflex is normal in both eyes • Total defect (no PL) = amaurotic pupil • Relative defect = Marcus Gunn pupil

Visual field defects

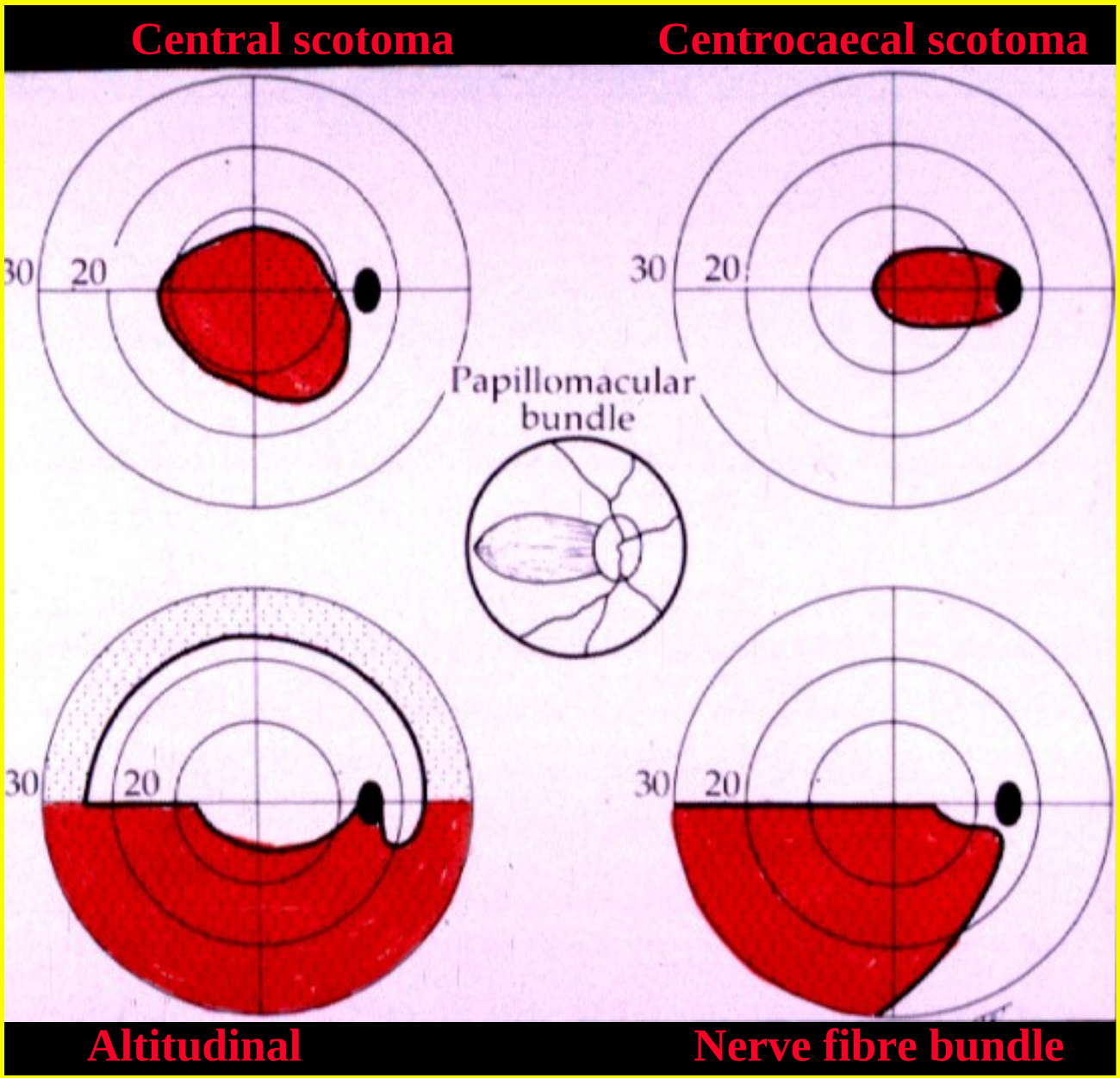

Optic disc changes

Normal	Swelling
· Retrobulbar neuritis · Early compression	· Papilloedema · Papillitis and neuroretinitis · AION
Optico-ciliary shunts	**Atrophy**
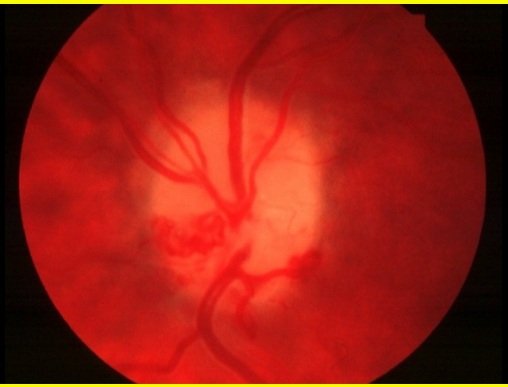	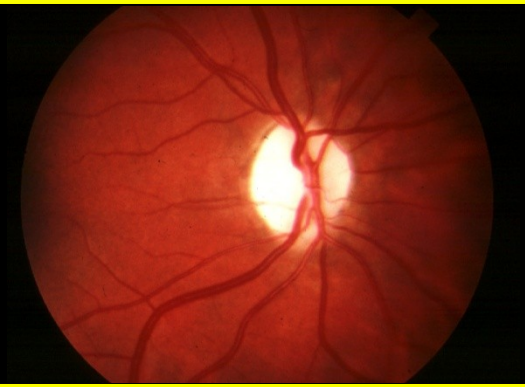
· Optic nerve sheath meningioma · Occasionally optic nerve glioma	· Postneuritic · Compression · Hereditary optic atrophies

Special investigations

MRI	Visually evoked potential
	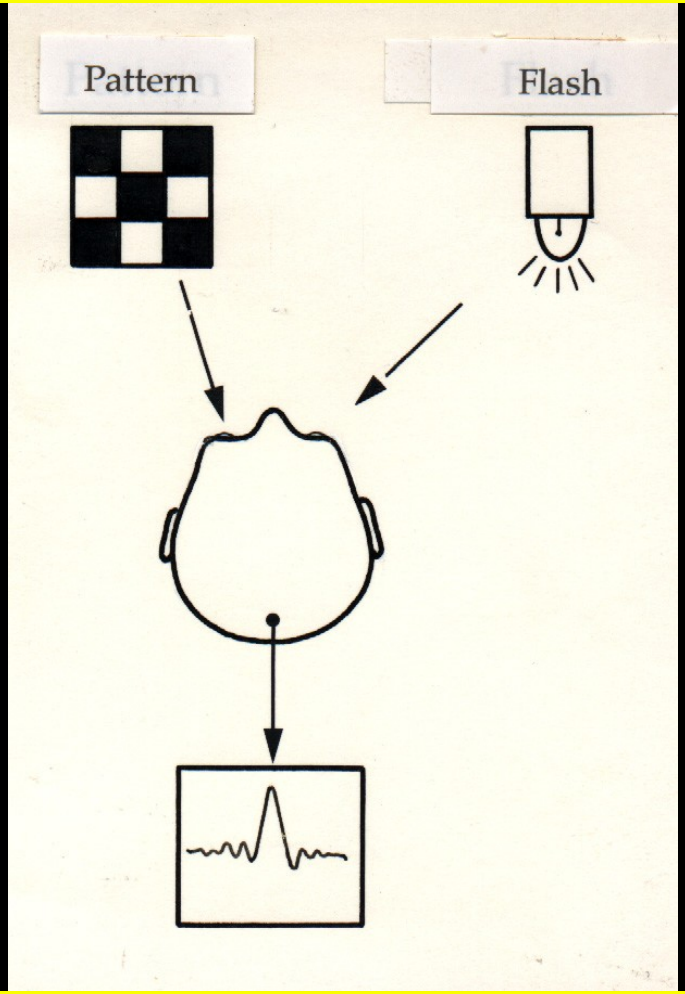
Orbital fat-suppression techniques in T1-weighted images	Assessment of electrical activity of visual cortex created by retinal stimulation

Classification of optic neuritis

Retrobulbar neuritis (normal disc)	Papillitis (hyperaemia and oedema)	Neuroretinitis (papillitis and macular star)
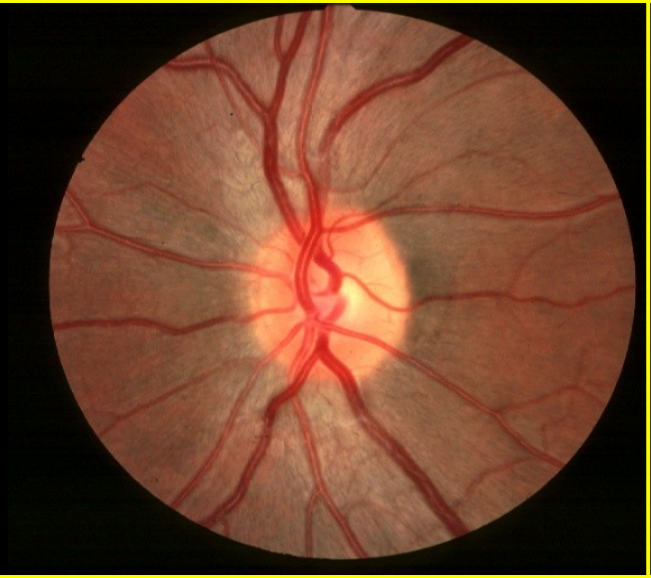	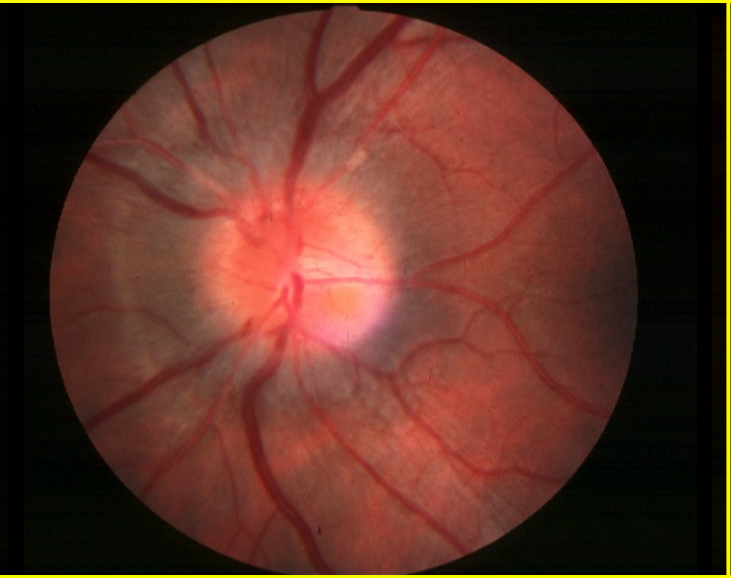	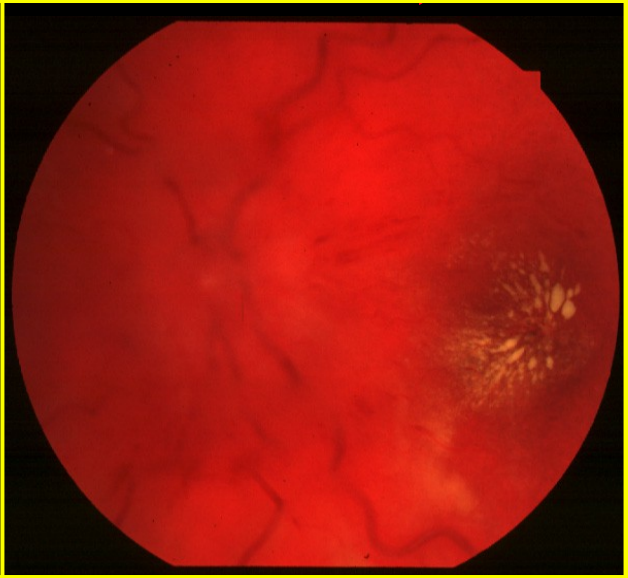
· Demyelination - most common · Sinus-related (ethmoiditis) · Lyme disease	· Viral infections and immunization in children (bilateral) · Demyelination (uncommon) · Syphilis	· Cat-scratch fever · Lyme disease · Syphilis

Non-arteritic AION

Presentation

- Age - 45-65 years
- Altitudinal field defect
- Eventually bilateral in 30% (give aspirin)

Acute signs	Late signs
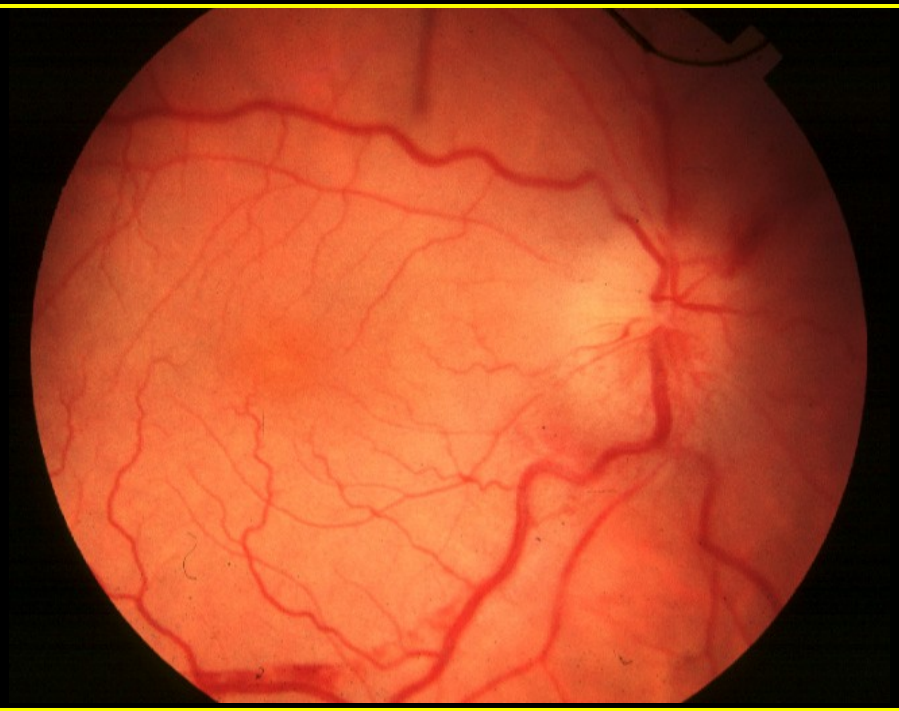	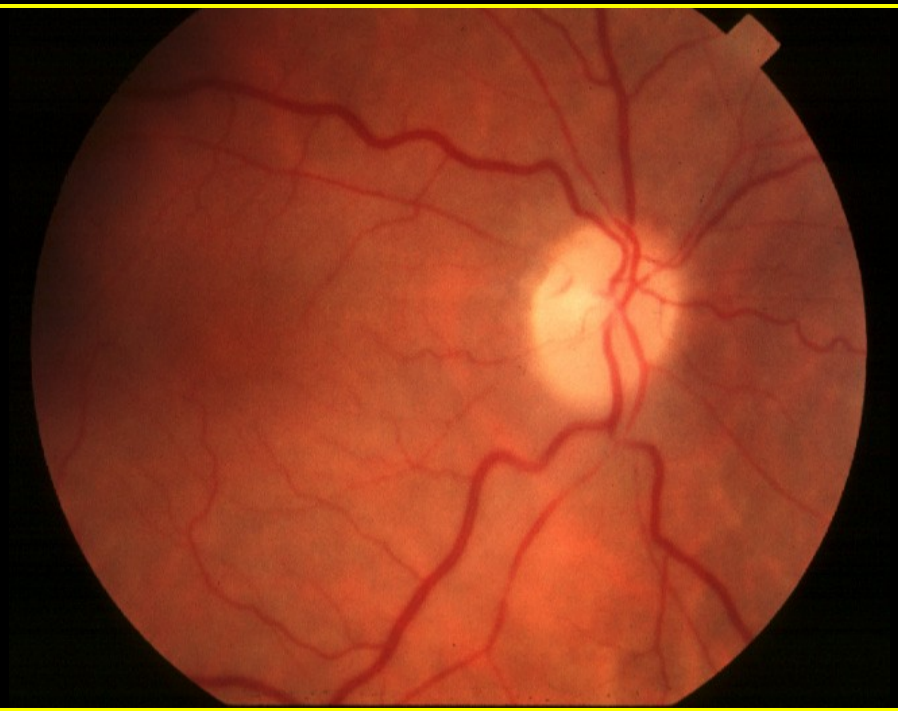
• Pale disc with diffuse or sectorial oedema • Few, small splinter-shaped haemorrhages	• Resolution of oedema and haemorrhages • Optic atrophy and variable visual loss

FA in acute non-arteritic AION

Localized hyperfluorescence

Increasing localized hyperfluorescence

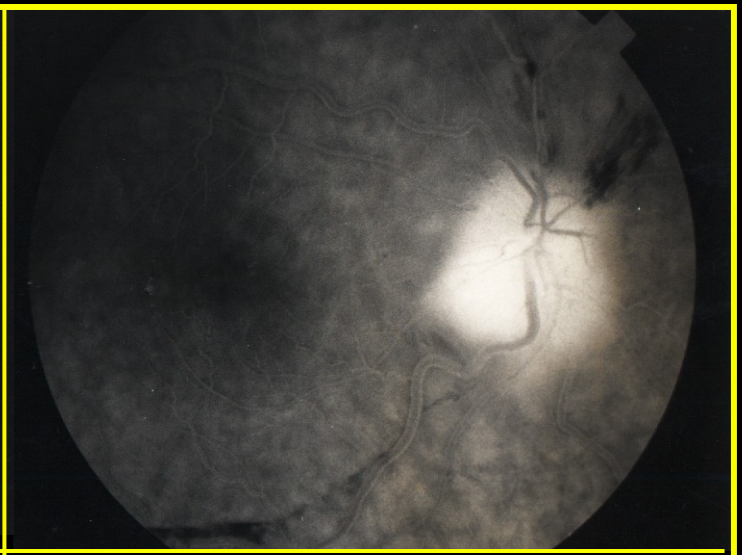

Generalized hyperfluorescence

Superficial temporal arteritis

Presentation

- Age - 65-80 years
- Scalp tenderness
- Headache
- Jaw claudication
- Polymyalgia rheumatica
- Superficial temporal arteritis
- Acute visual loss

Special investigations

- ESR - often > 60, but normal in 20%
- C-reactive protein - always raised
- Temporal artery biopsy

Histology of giant cell arteritis

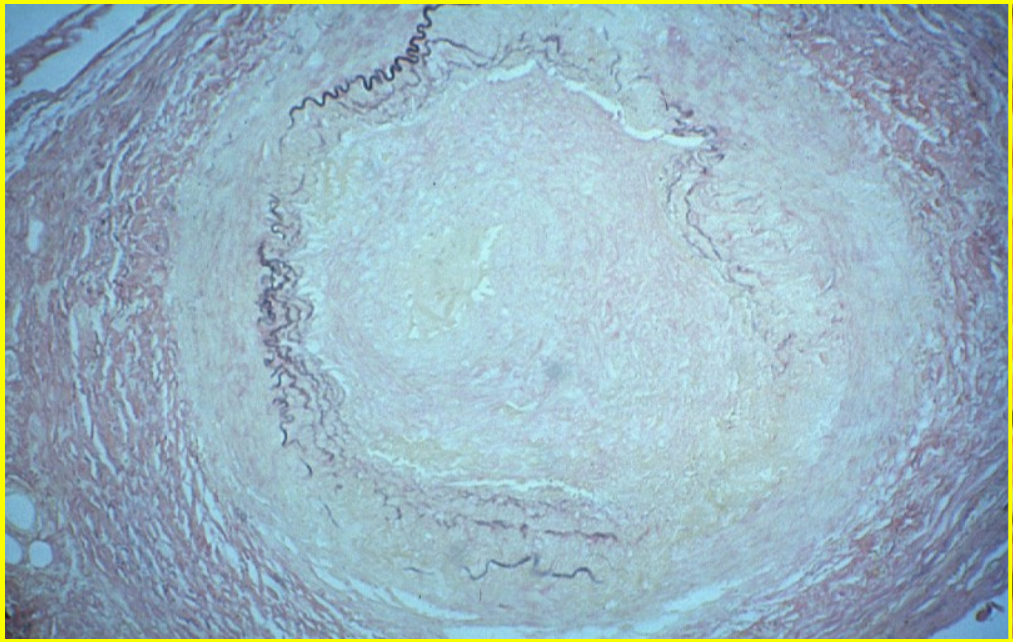

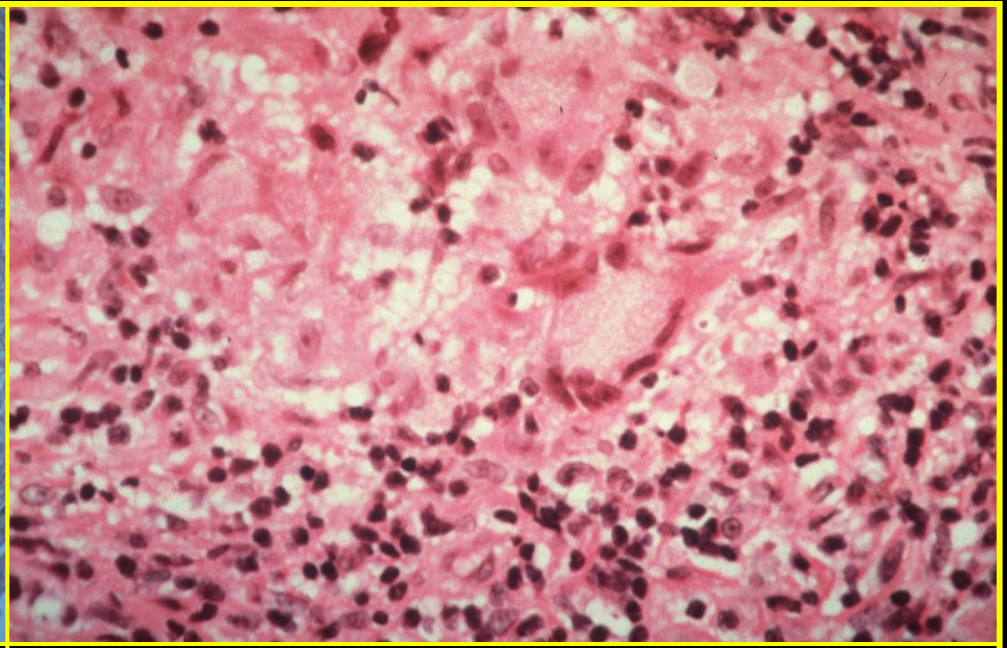

- Granulomatous cell infiltration
- Disruption of internal elastic lamina
- Proliferation of intima
- Occlusion of lumen

- High-magnification shows giant cells

Arteritic AION

- Affects about 25% of untreated patients with giant cell arteritis
- Severe acute visual loss
- Treatment - steroids to protect fellow eye
- Bilateral in 65% if untreated

- Pale disc with diffuse oedema
- Few, small splinter-shaped haemorrhages
- Subsequent optic atrophy

Leber hereditary optic neuropathy

Maternal mitochondrial DNA mutations

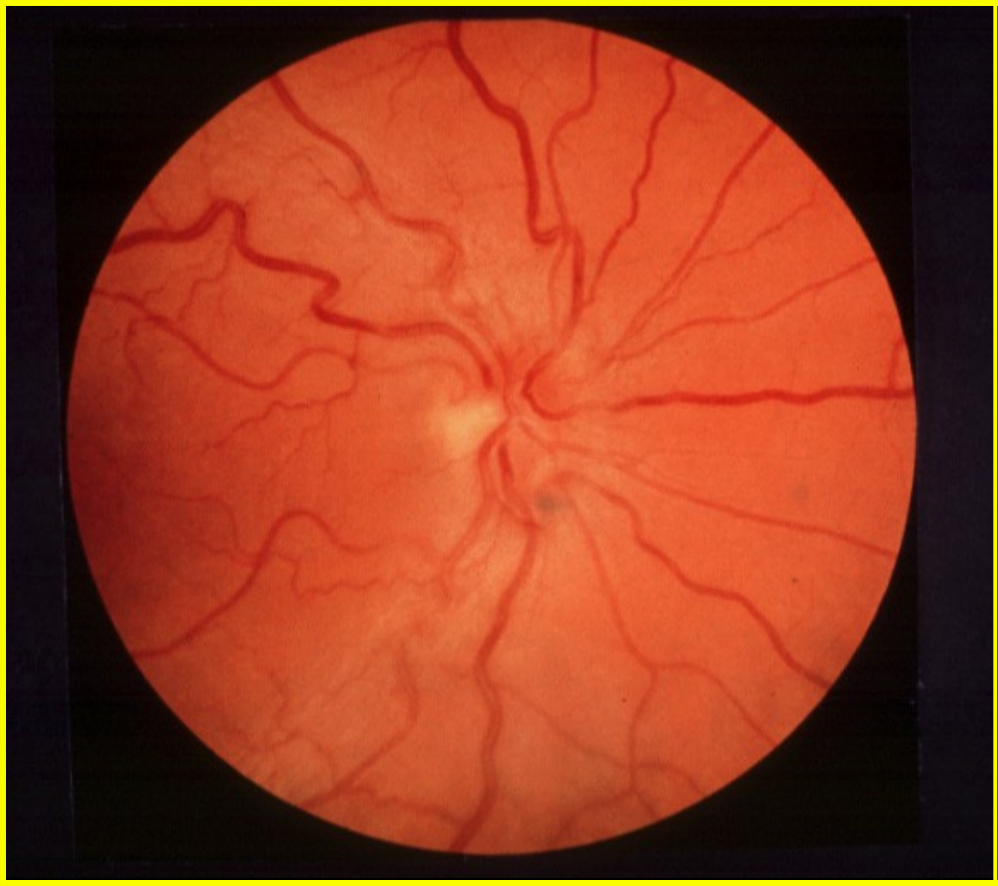

Presents

- Typically in males - third decade
- Occasionally in females - any age
- Initially unilateral visual loss
- Fellow eye involved within 2 months
- Bilateral optic atrophy

Signs

- Disc hyperaemia and dilated capillaries (telangiectatic microangiopathy)
- Vascular tortuosity
- Swelling of peripapillary nerve fibre layer
- Subsequent bilateral optic atrophy